

**POST-OPERATIVE NEUROLOGICAL RECOVERY PATTERN IN DEGENERATIVE CERVICAL MYELOPATHY AND RADICULOPATHY**Raju B. Mundhe<sup>1</sup>, Arvind B. Goregaonkar<sup>2</sup>, Anuraag G. Gupta<sup>3</sup>**HOW TO CITE THIS ARTICLE:**

Raju B. Mundhe, Arvind B. Goregaonkar, Anuraag G. Gupta. "Post-operative Neurological Recovery Pattern in Degenerative Cervical Myelopathy and Radiculopathy". Journal of Evolution of Medical and Dental Sciences 2015; Vol. 4, Issue 55, July 09; Page: 9518-9533, DOI: 10.14260/jemds/2015/1378

**ABSTRACT: OBJECTIVE:** To study the neurological recovery pattern and clinical recovery after surgical intervention in patients of degenerative cervical myelopathy and radiculopathy to know the surgical outcome, at Lokmanya Tilak Municipal Medical College, Mumbai, Maharashtra. **METHOD:** We carried out prospective and retrospective observational study of 30 patients with functional disability secondary to cervical degenerative myelopathy and radiculopathy who underwent surgery for decompression of the cervical spinal cord with or without spinal stabilization. March 2012 to March 2013 were studied and followed for more than 1year. All patients were operated by a single surgeon and reviewed independently. All the patients had received appropriate conservative management before undergoing surgical intervention. Data was analysed by using appropriate software. **RESULTS:** The study group comprised of 27 males and 3 females aged between 36 and 75 years with a mean age of 56 years that presented with functional disability secondary to cervical myelopathy and radiculopathy. Pain and neurological examination were used as criteria at sequential follow-ups. Functional outcome was assessed using Japanese Orthopaedic Association score, Oswestry Disability Index and Visual Analogue Scale. It was found that neurological recovery for myelopathy by mJOA score at intervals between 15 days to 3 months was significant after which recovery was occurring but was not significant. Anterior cervical discectomy with fusion for 1-2 levels has given good results than posterior laminectomy for 3 or more levels. Cervical radiculopathy alone has good recovery results after decompression surgery than myelopathy or myelopathy with radiculopathy. **CONCLUSION:** Based on this study, we found that the results of surgery for cervical spondylotic myelopathy and radiculopathy are excellent. The best neurological and functional recovery is seen in patients with mild to moderate functional disability at the time of surgery. Duration of symptoms preoperatively, age at presentation, number of levels involved affects the recovery. They are negatively correlated with recovery.

**KEYWORDS:** Degenerative cervical myelopathy and radiculopathy, Neurological recovery.

**INTRODUCTION:** Cervical degenerative disease or cervical spondylosis refers to age related degenerative changes within the cervical spinal column.<sup>(1)</sup> Approximately 25% of the individuals <40 years of age, 50% of individuals over 40 years of age, and 85% of individuals over 60 years of age have some degree of disc degeneration.<sup>(2)</sup> In fact the condition is becoming more prevalent as life expectancy increases. This condition is often asymptomatic, but in 10-15% of patients the degeneration results in compression of the spinal cord or the nerves presenting symptomatically as cervical myelopathy or radiculopathy.<sup>(3)</sup>

Cervical spondylotic myelopathy (CSM) refers to a clinical syndrome of long tract signs in the upper and lower extremities arising from a combination of static and dynamic compression due to disc herniation, osteophyte formation, hypertrophy of facet joints and hypertrophy of ligaments, as well as due to vascular phenomenon. In 1952, Spillane and Lloyd reported that the course of cervical

## ORIGINAL ARTICLE

---

myelopathy in their patients appeared to be one of progressive disability.<sup>(4)</sup> In a 1956 report on 120 patients with cervical spondylotic myelopathy, Clarke and Robinson stated their belief that once the disorder was recognized, neurologic function never returned to normal.<sup>(5)</sup> Of their patients, 75% had episodic progression, 20% showed slow steady progression, and 5% had a rapid onset of symptoms followed by a lengthy period of stability. Sensory and bladder changes tended to be transient, but motor changes tended to persist and progress over time.

Cervical spondylotic radiculopathy (CSR) refers to symptoms in a specific dermatomal distribution in the upper extremity. Patients describe sharp pain, tingling, or burning sensations in the involved area. There may be sensory or motor loss corresponding to the nerve root involved, and reflex activity may be diminished. Traditionally, non-operative management such as physical therapy, cervical immobilization and anti-inflammatory drug has been the preferred and often the only required intervention. Surgical treatment has been reserved for patients who have progressive neurological symptoms and moderate to severe functional disability. The goal of surgery is to decompress the spinal cord and nerve roots whilst providing a stable spine. The surgical approach is decided by the direction of the compression, the number of levels involved, the sagittal alignment of the cervical spine and the presence or absence of instability and axial neck pain. The posterior approach has traditionally been favored for patients with multilevel cervical stenosis with dorsal cord compression and a well maintained cervical lordosis. Anterior surgery is preferred for patients with ventral cord compression resulting in localized areas of stenosis, instability or kyphotic deformity and in those with significant neck pain. However, there has been a considerable variation in the neurological recovery reported following these procedures. This study was designed for post-operative neurological recovery pattern in patients with cervical spondylotic myelopathy and radiculopathy following anterior, posterior or circumferential approach to cervical decompression and fusion.

### **AIMS AND OBJECTIVE:**

1. To study the neurological and clinical recovery pattern in degenerative cervical myelopathy and radiculopathy after surgical intervention to know the surgical outcome.
2. To study the predictors of neurological and clinical recovery in degenerative cervical myelopathy and radiculopathy after surgical intervention.

**MATERIALS AND METHOD:** A consecutive series of 30 patients with functional disability secondary to cervical degenerative myelopathy and radiculopathy underwent surgery for decompression of the spinal cord with or without spinal stabilization from March 2012 till March 2013 were studied and followed for 1 year at least. All patients were operated by a single surgeon and reviewed independently. All the patients had received appropriate conservative management before undergoing surgical intervention.

The ethics committee approved the study plan and informed consent was obtained from all patients before the operation.

### **Inclusion Criteria:**

1. All patients who were diagnosed with degenerative cervical myelopathy and radiculopathy and did not improve in spite of appropriate conservative management and progressed to functional disability.
2. Involvement of sub-axial cervical spine.
3. Age >30 years and <80 year.

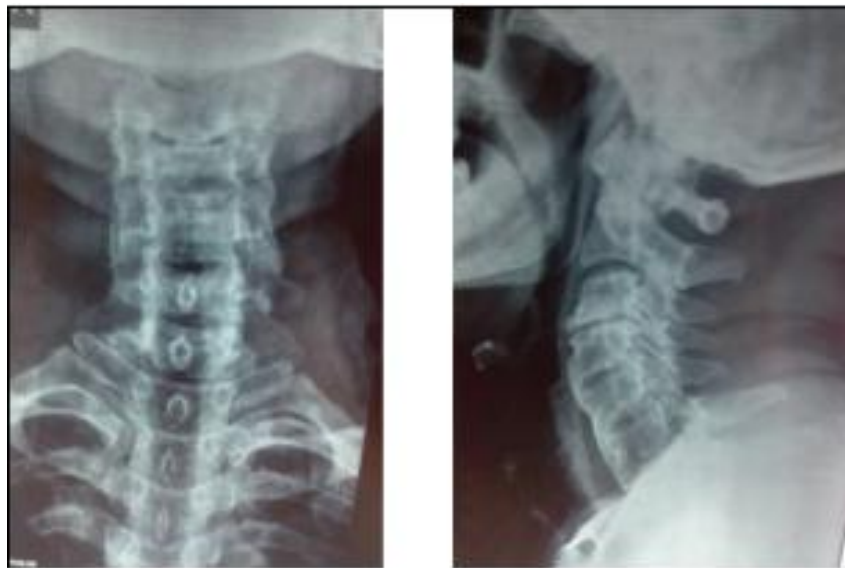## ORIGINAL ARTICLE

**Exclusion Criteria:** Patients, otherwise meeting the inclusion criteria, were ineligible in case of any of the following criteria.

1. Myelopathy secondary to medical causes (e.g, vascular, connective tissue disorder, infection).
2. Traumatic myelopathy.
3. Congenital myelopathy.
4. Previous history of cervical spine surgery.
5. Psychiatric disorders.
6. Definite diagnosis not established.
7. Hemodynamically, medically unstable patients.

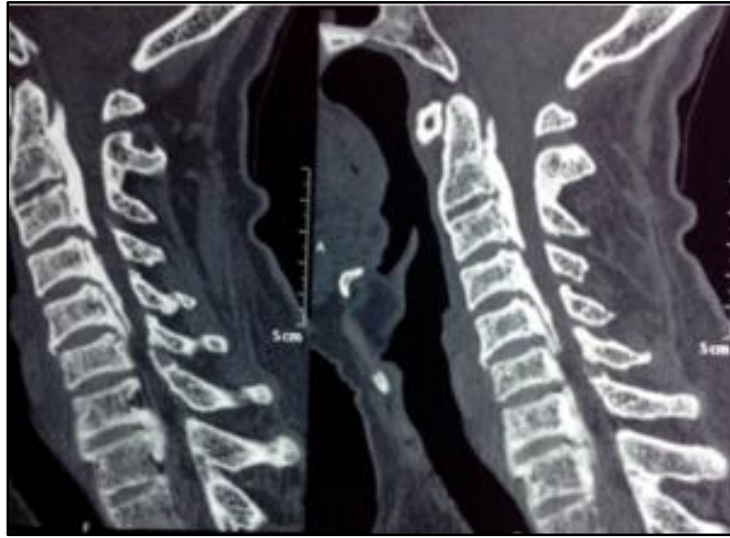**Management Protocols:** All patients were pre-operatively investigated in the following ways:

- Detailed history about the nature of symptoms.
- Pain Characteristics like site, intensity (Visual Analogue Scale), type, aggravation and relieving factors, radiation, frequency of medication, activity level.
- Neurological examination.
  - Nutrition.
  - Tone.
  - Power in upper and lower limbs.
  - Reflexes-superficial: Deep.
  - Sensations.
  - Bladder bowel complaints.
- Range of motion flexion extension
- **Radio Imaging:** These patients were studied with radiographs–plain antero-posterior and Lateral and if needed flexion-extension.



**Antero- posterior & lateral radiograph of a 65 years old male showing degenerative changes (osteophytes, reduced disc height) and decreased canal diameter**

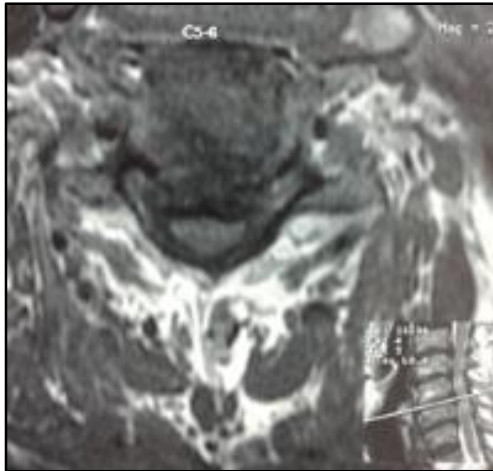
## ORIGINAL ARTICLE



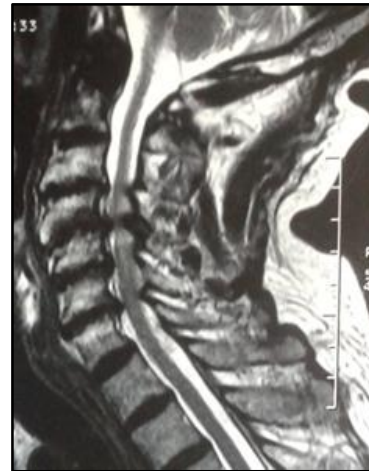CT scan showing cervical canal stenosis (Osteophytes, ossified posterior longitudinal ligament, reduced disc height)

**Magnetic Resonance Imaging (MRI) scans:** M.R.I imaging was employed to identify specific anatomic pathology. Detailed imaging in the sagittal, axial and coronal planes was obtained.

These are M.R.I scans of a patient who had multilevel cervical Cord compression.



Transverse cut showing circumferential cord compression at C5-6 level (T2W Image)



Sagittal cut showing multilevel [C3-7] cervical cord compression with maintained cervical lordosis (T2W)

The study group comprised of 27 males and 3 females aged between 36 and 75 years with a mean age of 56 years that presented with functional disability secondary to cervical myelopathy and radiculopathy. The diagnosis of CSM and CSR was subsequently established clinically and radiologically. The patients had been symptomatic for a period of 5 to 48 months before presenting to our clinic. Almost all of them had received some form of non-operative treatment prior to seeing us.

## ORIGINAL ARTICLE

---

When they presented to us, the most common symptoms were parasthesia/dysesthesia in the hands and feet, gait difficulties that often resulted in stumbling and falling, clumsiness of the hand resulting in inability to carry out fine motor function such as combing one's hair or buttoning the shirt. Complaints of neck stiffness, axial neck pain, shoulder pain, occipital headaches, radicular arm pain. Bladder complaints in the form of hesitancy, frequency were seen in few of the patients whilst some of the patients were unable to ambulate at presentation and some patients required a walking aid.

After confirming the diagnosis clinically and radiologically surgical intervention was planned. All patients were operated by a single surgeon and reviewed independently. Surgery was done by a senior spine specialist for a definite diagnosis. Patients were operated in prone position for laminectomy using posterior approach and supine position for anterior approach using left lateral transverse incision.

**Follow up:** Pain and neurological examination were used as criteria at sequential follow -ups. Functional outcome was assessed using Japanese Orthopaedic Association score, Oswestry Disability Index and Visual Analogue Scale.

The clinical condition of the patient was graded using the modified Japanese Orthopaedic Association score (mJOA score).<sup>(6)</sup> The Benzel's modification of the Japanese Orthopaedic Association Score is a validated outcome measure that semi-quantitatively represents the ambulatory status of the patient and his ability to function independently. The mJOA score may range from 0 to 18 with higher scores representing a more preserved neurological and functional status. The average pre-operative mJOA score in our series was 11.4 (Range: 7 to 13). Based on the mJOA score, the disability of the patient was graded.

**Surgery:** Patients with moderate to significant disability secondary to CSM or those patients with mild disability that had failed to improve with non-operative treatment were selected for surgery. Based upon the direction of spinal cord compression, the number of spinal segments involved, the sagittal alignment of the cervical spine and the presence or absence of spinal instability and axial neck pain, the patients underwent one of three different operations:

1. Anterior cervical discectomy and fusion-ACDF Anterior cervical corpectomy and fusion-ACCF.
2. Posterior multilevel laminectomy-PL.
3. Anterior cervical decompression and fusion + posterior laminectomy (ACDF+PL).

The anterior approach was chosen in 22 patients with primarily anterior compression restricted to a maximum of two levels of spinal cord. The posterior approach was chosen in 8 patients with  $\geq 3$  levels of spinal cord compression when the sagittal alignment of the cervical spine was neutral or lordotic.

All data regarding the surgeries such as blood loss, surgery time, intra-operative and post-operative complications were collected. Patients were clinically and radiologically assessed and evaluated using the mJOA scores, ODI scores and VAS scores during the 1year follow-up.

Recovery rate of the JOA score (Hirabayashi method)<sup>(7)</sup> Recovery rate(%) =  $[\text{preoperative score} - \text{postoperative score}] / [\text{fullscore (18)} - \text{preoperative score}] \times 100$ .

Achieved(JOA) score: Achieved score(points) =  $\text{postoperative score} - \text{preoperative score}$ .<sup>(8)</sup>[The lower the score the more severe the deficits].

## ORIGINAL ARTICLE

### RESULTS:

Age(years)	Percentage	No.
36 to 59 years	60.0%	18
>= 60 years	40.0%	12
<b>Total</b>	<b>100.0%</b>	<b>30</b>

**Table 1-Distribution among cases of – Age(years)**

Sex	No.	Percentage
Female	3	10.0%
Male	27	90.0%
<b>Total</b>	<b>30</b>	<b>100.0%</b>

**Table 2-Distribution among cases of – sex**

Diagnosis	No.	Percentage
Myelopathy	26	86.7%
Radiculopathy	4	13.3%
<b>Total</b>	<b>30</b>	<b>100.0%</b>

**Table 3-Distribution among cases of – diagnosis**

No. of levels involved	No.	Percentage
1	18	60.0%
2	4	13.3%
4	8	26.7%
<b>Total</b>	<b>30</b>	<b>100.0%</b>

**Table 4-Distribution among cases of – number of levels involved**

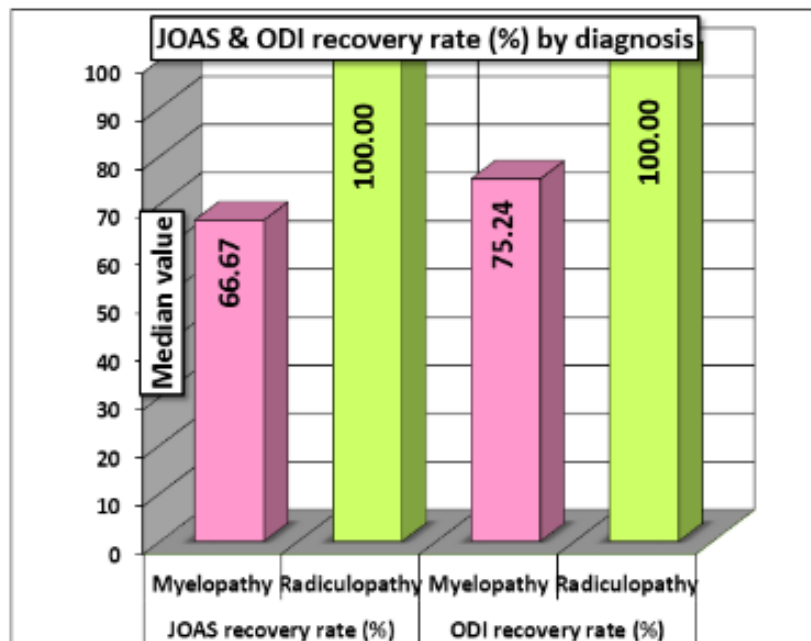
In above tables patients were distributed in study according to age, sex, diagnosis and number of levels involved.

Variables ^	Diagnosis	No.	Mean	SD	Median	IQR		
JOAS recovery rate (%)	Myelopathy	26	65.36	23.51	66.67	33.3 3	-2.828	0.004 69
	Radiculopathy	4	100.00	0.00	100.00	0.00	Difference is significant	
ODI recovery rate (%)	Myelopathy	26	71.14	18.61	75.24	20.8 3	-2.942	0.003 26
	Radiculopathy	4	100.00	0.00	100.00	0.00	Difference is significant	

**Table 5-Comparison of recovery rate (%) by diagnosis**

Table 5 shows JOAS recovery rate and ODI recovery rate for radiculopathy is faster than myelopathy i.e. significant difference, which is presented in graph – 1.

## ORIGINAL ARTICLE



Graph 1

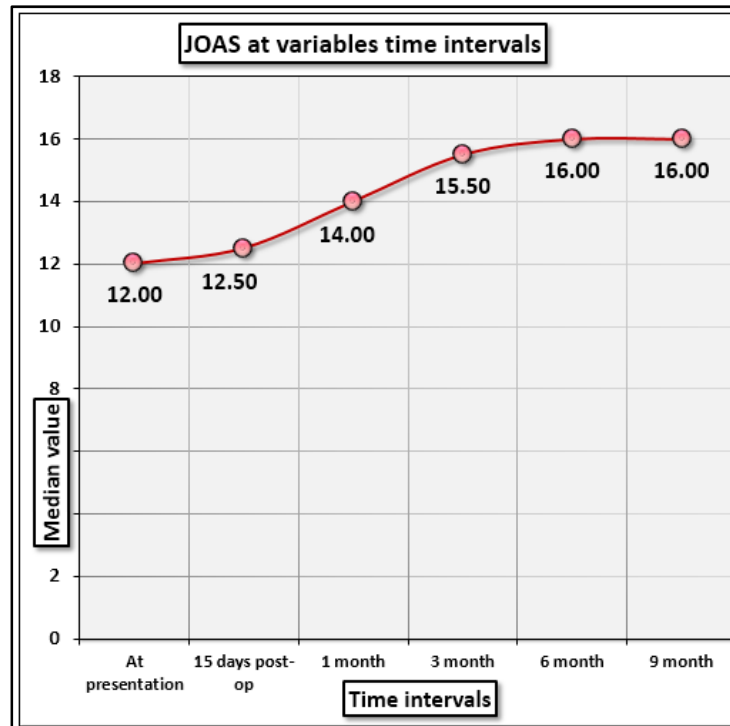
OAS-	Mean	SD	Median	IQR		
At presentation	11.40	2.09	12.00	4.00	138.001	4.76E-28
15 days post-op	12.23	2.47	12.50	3.25	<b>Difference is Significant</b>	
1 month	13.47	2.40	14.00	4.25		
3 month	14.90	2.30	15.50	3.00		
6 month	15.67	2.17	16.00	3.25		
1year	15.83	2.14	16.00	3.25		

Table 6A-Comparison of JOA score at variable time intervals among the cases

Comparison pairs	Difference of Ranks	Q-value	p-value	Difference is-
At presentation vs. 15 days PO	13.500	1.317	> 0.05	Not significant
At presentation vs. 1 month	45.500	4.440	<= 0.05	Significant
At presentation vs. 3 months	87.500	8.539	<= 0.05	Significant
15 days PO vs. 1 month	32.000	3.123	> 0.05	Not significant
15 days PO vs. 3 months	74.000	7.222	<= 0.05	Significant
1 month PO vs. 3 months	42.000	4.099	<= 0.05	Significant
1 month PO vs. 6 months	69.500	6.783	<= 0.05	Significant
3 months PO vs. 6 months	27.500	2.684	> 0.05	Not significant
3 months PO vs. 9 months	32.000	3.123	> 0.05	Not significant
6 months PO vs. 1year	4.500	0.439	> 0.05	Not significant


Table 6B: All Pairwise Multiple Comparison Procedures(Tukey Test):

## ORIGINAL ARTICLE



Graph 2

It was found that neurological recovery by JOA score at intervals between 1 to 3 months was significant compared to first 1 month and 3 to 9 months of post-surgery after which it follows plateau.



Graph 3

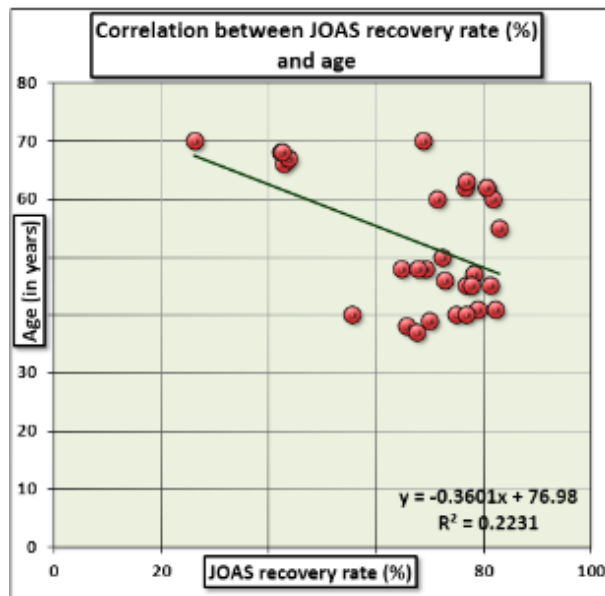


## ORIGINAL ARTICLE

It was found that neurological recovery in radiculopathy occurs faster than myelopathy and attains plateau earlier.

Variability	Spearman's rho	Age (years)	No. of levels involved	Time since symptomatic (months)	JOAS recovery rate (%)	ODI recovery rate (%)
Age(years)	Correlation Coefficient	1	.368(*)	.439(*)	-.521(**)	-.548(**)
	p-value	.	0.0455	0.0151	0.0031	0.0017
No. of levels involved	Correlation Coefficient	.368(*)	1	0.284	-.784(**)	-.701(**)
	p-value	0.0455	.	0.128	1.00E-06	1.57E-05
Time since symptomatic (months)	Correlation Coefficient	.439(*)	0.284	1	-.453(*)	-.377(*)
	p-value	0.0151	0.128	.	0.012	0.0401
JOAS recovery rate (%)	Correlation Coefficient	-.521(**)	-.784(**)	-.453(*)	1	.877(**)
	p-value	0.0031	#####	0.012	.	1.00E-06
ODI recovery rate (%)	Correlation Coefficient	-.548(**)	-.701(**)	-.377(*)	.877(**)	1
	p-value	0.0017	#####	0.0401	1.00E-06	.
* Correlation is significant at the 0.05 level (2-tailed).						
** Correlation is significant at the 0.01 level (2-tailed).						
<b>Table 7-Nonparametric correlation between various variables</b>						

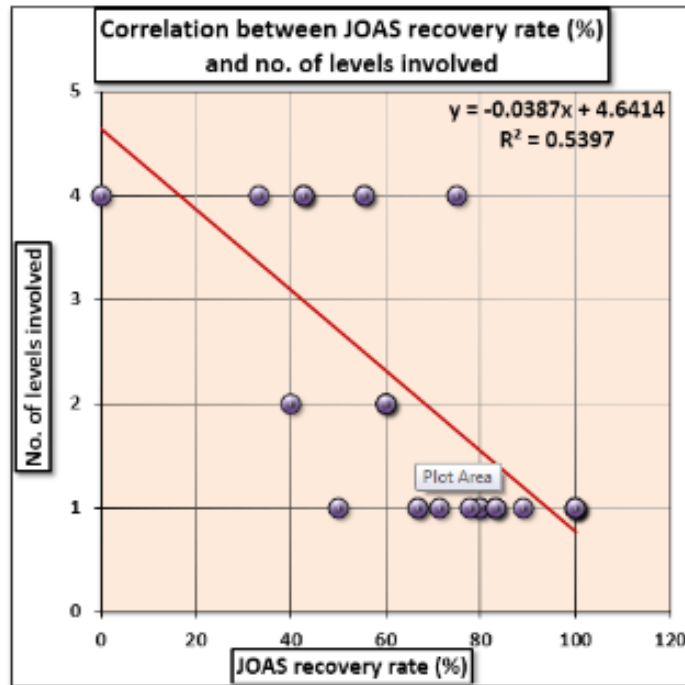
It was found that age, number of levels involved, time since symptomatic were correlated with JOA score and ODI recovery rate (Negative correlation).



**Graph 4**

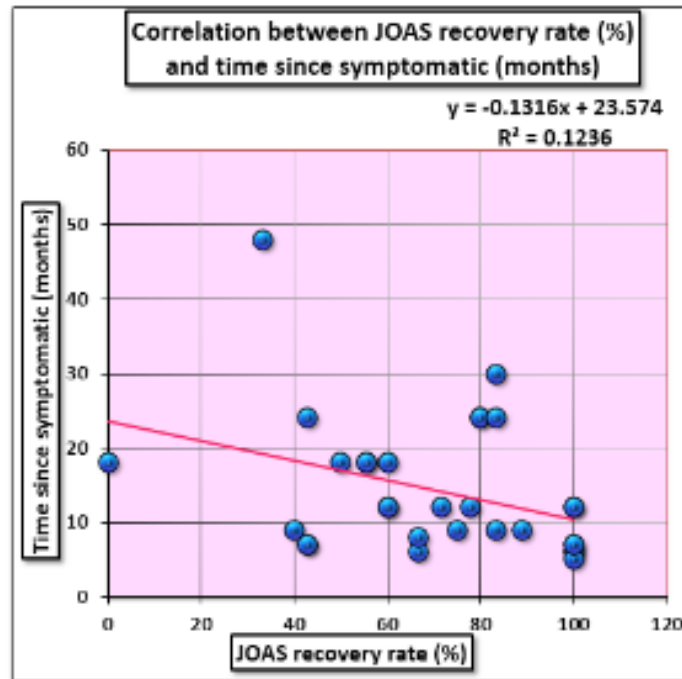
## ORIGINAL ARTICLE

It was found that as age of the patient increases neurological recovery rate using JOA score for myelopathy and radiculopathy decreases.



**Graph 5**

It was found that as number of levels involved increases neurological recovery rate using JOA score for myelopathy and radiculopathy decreases.



**Graph 6**

## ORIGINAL ARTICLE

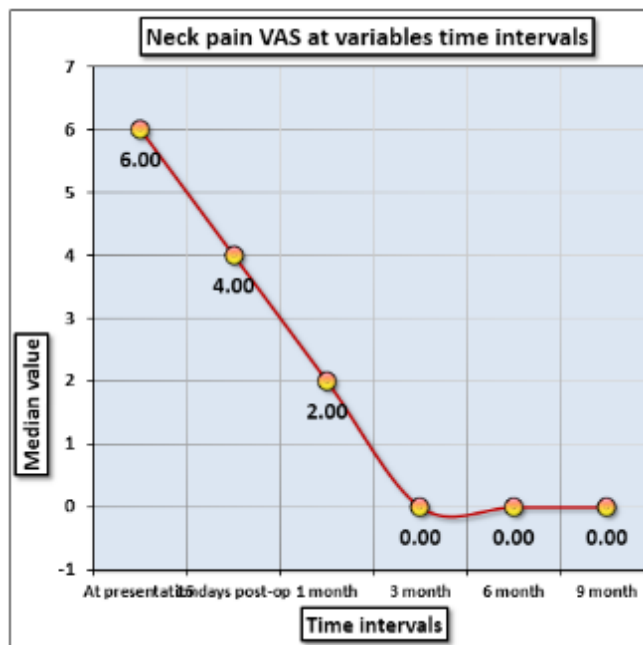
It was found that as duration of symptoms increases neurological recovery rate(JOAS) decreases for myelopathy and radiculopathy.

Neck pain VAS-	Mean	SD	Median	IQR		
At presentation	5.87	1.28	6.00	2.00	140.895	1.15E-28
15 days post-op	4.37	1.71	4.00	2.25	<b>Difference is Significant</b>	
1 month	2.50	1.59	2.00	1.50		
3 month	1.10	1.45	0.00	2.00		
6 month	0.77	1.19	0.00	1.25		
1year	0.67	1.09	0.00	1.00		
<b>Note: Friedman Repeated Measures ANOVA on Ranks applied.</b>						
<b>Table 8A-Comparison of Neck pain VAS at variables time intervals among the cases</b>						

Comparison Pairs	Difference of Ranks	Q-value	p-value	Difference is-
At presentation vs. 15 days PO	25.000	2.440	> 0.05	Not significant
At presentation vs. 1 month	57.500	5.611	<= 0.05	Significant
At presentation vs. 3 months	105.500	10.296	<= 0.05	Significant
15 days PO vs. 1 month	32.500	3.172	> 0.05	Not significant
1 month PO vs. 3 months	48.000	4.684	<= 0.05	Significant
3 months PO vs. 6 months	11.500	1.122	> 0.05	Not significant
3 months PO vs. 9 months	15.500	1.513	> 0.05	Not significant
6 months PO vs. 1year	4.000	0.390	> 0.05	Not significant
<b>Table 8B-All Pairwise Multiple Comparison Procedures(Tukey Test):</b>				

It was found that neck pain was decreasing upto first 3 months of post-surgery and then becomes slow to decrease.

## ORIGINAL ARTICLE



**Graph 7**

It was found that neck pain was decreasing upto 3 months post-surgery then it was plateau.

**DISCUSSION:** In our study, the anterior approach was chosen when the disease was limited to a maximum of two spinal segments. We performed a anterior discectomy with fusion when disease was at the level of the intervertebral disc, compression was milder, there was no congenital stenosis and the cervical sagittal alignment was lordotic. On the other hand a corpectomy was performed when compression was more severe or retrovertebral, there was congenital stenosis or the sagittal alignment was kyphotic. Smith-Robinson, Bailey and Badgley and Cloward popularized the anterior approach for decompression and fusion at one or two levels in the cervical spine. Others have successfully used it for patients undergoing multilevel fusion.<sup>(9)(10-12)</sup>.

Following surgery, there was significant neurological and functional improvement in all patients in this group. The overall analysis of our series showed an initially rapid neurological recovery during the first 3 months after surgery. Subsequently, the result obtained at 3 months after surgery only improved very slightly, with the curve nearly leveled off, with patients progressing little beyond the sixth month. This recovery process describes an analogue curve, whatever the severity of the initial deficit. On average, patients presenting a very severe initial deficit show the same recovery process as patients with less severe impairment but final score achieved in former was less than later.

Therefore, the fact that neurological recovery after decompression surgery that begins early and rapidly progresses during the first 3 months after surgery should be motivated to set up a specific multidisciplinary neurological rehabilitation program (Ergotherapy, gait and balance work, sphincter rehabilitation) beginning in the early postoperative period.

Many publications have evaluated the more or less long-term results of cervical cord decompression surgery in myelopathy. We found no studies evaluating the speed of this recovery. Seichi et al.<sup>(13)(14)</sup> showed that the JOA score remains stable after 1 year postoperative, Neurological

## ORIGINAL ARTICLE

---

recovery, when evaluated by JOA score, progresses a mean of 5 points. It seems relatively constant whatever the severity of the initial neurological deficit. In our series, neurological recovery progressed a mean of 4.43 and median of 4 on the mJOA scale. The severe forms of cervical myelopathy did not appear to be negative indications for surgery. Matsuda et al.<sup>(14)</sup> came to the same conclusion when they evaluated the postoperative progression of patients over 75 years of age. The preoperative JOA score of their patients is more severe than for those under 65 years of age, but the gain in quality of life is high and the increase in the postoperative JOA score was in the neighborhood of 5 points, on average. The results expressed in this study are based on the JOA score.

The pre-op mJOA score in group of 22 patients undergoing anterior surgery was 12.04 which improved to 16.73 at last follow-up after 1 year. These results were comparable to those reported by Wada et al. who reported an improvement in mJOA scores from 7.9 to 13.3 at 1 year follow-up in 23 patients that underwent ACCF. That means both studies were comparable and showed 4-5 points recovery. Comparing these studies it seems that points of recovery were more in patients with less preoperative score but final attained score was more in patients with higher preoperative score. Emery et al also reported a high rate of pain relief, neurological and functional improvement in 108 patients that underwent anterior discectomy or partial or subtotal corpectomy for CSM. They correlated good outcomes with milder pre-operative neurologic deficit and disability whilst recurrent myelopathy was co-related with a non-union. In our study we were also compared the results of radiculopathy with myelopathy. Radiculopathy alone had quicker recovery and attained higher JOA score than myelopathy or myelopathy with radiculopathy. Recovery rate for radiculopathy alone was 100% as compared with 66.67% for myelopathy.

The patient with the neurological deterioration showed significant neurological improvement but continued to have a mild disability even at last follow-up. At long-term follow-up, 3 patients developed radiological evidence of adjacent level degeneration with reduction in disc height, anterior and posterior osteophytes. One of these patients was asymptomatic, a second had mild axial neck pain which was treated symptomatically. A third patient developed a prolapsed disc at the adjacent segment and developed radicular arm pain which settled with non-operative treatment.

Posterior surgery, ie, laminectomy has for long been the treatment for multilevel cervical spondylotic myelopathy. It allows excellent decompression of the spinal cord, is safe and quick. Hence it is the preferred method of decompression in the elderly. Potential adverse outcomes of laminectomy include instability and epidural scar formation which may result in post-operative neck pain or headache.

In our series, 8 patients underwent laminectomy. The pre-operative mJOA score that underwent posterior surgery alone was 9.63. Post-operative the mJOA score improved to 13.37. Houten et al. evaluated 38 patients who underwent laminectomy and lateral mass plating for CSM.<sup>(15)</sup> Significant improvement in neurological function occurred in 97% of patients. The mJOA score improved from 12.9 to 15.6 at a mean follow up of 1 year. Complications included a C5 nerve root palsy. Here also points of recovery are more with severe neurodeficit but final achieved score is less and our study shown comparable results. In the group that underwent posterior surgery, we have had one patient who had foraminal osteophytes but no radicular pain pre-operatively, developed arm pain post-operatively. This patient was given intravenous solumedrol over 48 hours before the pain settled down. One patient had a drop in neurology immediately post-operative who not shown neurological recovery on follow up. One patient had a C5 nerve root palsy which recovered over a period of three months.

## ORIGINAL ARTICLE

---

In our study we also studied the VAS score for pain relief and ODI score for improvement of overall disability of patient. Patients with radiculopathy alone got quicker pain relief than myelopathy or myelopathy with radiculopathy. Pain relief was more in first 3 months after which very few patients required medicine for pain relief. ODI score also showed the results more or less parallel to JOA score but it measured actual functional capacity of doing daily activities. This was assessed by ODI recovery rate, 3 patients with less than 40% recovery were moderately disabled. 6 patients with around 60% recovery were mildly disabled. And remaining 21 patients were returned to their occupation.

In our study factors like age, duration of symptoms, number of levels involved were correlated with neurological recovery. mJOA score, ODI score recovery had negative correlation with these factors. Sex of the patient, level of compression had no correlation with neurological recovery of patient.

Our study is a single surgeon based consecutive cohort of patients studied and reviewed independently using valid outcome measures. The study group is large and helps us to study the role of surgery in CSM whilst comparing the results and complications following different surgical approaches.

**CONCLUSION AND SUMMARY:** Recovery from cervical spondylotic neurological deficit occurs rapidly following first 3 months of decompression surgery and stabilizes thereafter till 6 to 9 months of surgery. So, rehabilitation should begin early to optimize this neurological recovery. Severe deficit seems to follow the same process and levels off at a lower neurological level.

Anterior cervical discectomy with fusion for 1-2 levels has given good results than posterior laminectomy for 3 or more levels. Cervical radiculopathy alone has good recovery results after decompression surgery than myelopathy or myelopathy with radiculopathy.

Duration of symptoms preoperatively, age at presentation, number of levels involved affects the recovery. They are negatively correlated with recovery. Sex of the patient and level of involvement has no correlation with recovery pattern. Severe neurodeficit at presentation also follows the same pattern of recovery. But attains lower mJOA score at 1year than patients with less neurodeficit at presentation. ODI score recovery rate also follows the same pattern of functional improvement and parallels to JOA recovery rate. Radicular pain relief occurs earlier than neck pain as measured by visual analogue scale.

Based on this study, we found that the results of surgery for cervical spondylotic myelopathy are excellent. The best neurological and functional recovery is seen in patients with mild to moderate functional disability at the time of surgery.

### **BIBLIOGRAPHY:**

1. Roh JS, Teng AL, Yoo JU, Davis J, Furey C, Bohlman HH. Degenerative disorders of the lumbar and cervical spine. *Orthop Clin North Am.* 2005 Jul;36(3):255-62.
2. Matsumoto M, Fujimura Y, Suzuki N, Nishi Y, Nakamura M, Yabe Y, et al. MRI of cervical intervertebral discs in asymptomatic subjects. *J Bone Joint Surg Br.* 1998 Jan;80(1):19-24.
3. Bednarik J, Kadanka Z, Dusek L, Novotny O, Surelova D, Urbanek I, et al. Presymptomatic spondylotic cervical cord compression. *Spine(Phila Pa 1976).* 2004 Oct 15;29(20):2260-9.
4. Spillane JD, Lloyd GH. The diagnosis of lesions of the spinal cord in association with osteoarthritic disease of the cervical spine. *Brain.* 1952 Jun;75(2):177-86.

## ORIGINAL ARTICLE

---

5. Clarke E, Robinson PK. Cervical myelopathy: a complication of cervical spondylosis. *Brain*. 1956 Sep;79(3):483-510.
6. An objective assessment scale quantitating the severity of CSM(Benzel EC, Lancon J, Kesterson L, Hadden T: Cervical laminectomy and dentate ligament section cervical spondylotic myelopathy-*J Spinal Disorders* 1991;4: 286-295)
7. Hirabayashi K, Watanabe K, Wakano K, Suzuki N, Satomi K, Ishii Y. Expansive open-door laminoplasty for cervical spinal stenotic myelopathy. *Spine(Phila Pa 1976)*. 1983 Oct;8(7): 693-9.
8. Machino M, Yukawa Y, Hida T, Ito K, Nakashima H, Kanbara S, et al. Can elderly patients recover adequately after laminoplasty?: a comparative study of 520 patients with cervical spondylotic myelopathy. *Spine(Phila Pa 1976)*. 2012 Apr 15;37(8):667-71.
9. Yonenobu K, Fuji T, Ono K, Okada K, Yamamoto T, Harada N. Choice of surgical treatment for multisegmental cervical spondylotic myelopathy. *Spine(Phila Pa 1976)*. 1985 Oct;10(8):710-6.
10. Hanai K, Fujiyoshi F, Kamei K. Subtotal vertebrectomy and spinal fusion for cervical spondylotic myelopathy. *Spine(Phila Pa 1976)*. 1986 May;11(4):310-5.
11. Seifert V, Stolke D. Multisegmental cervical spondylosis: treatment by spondylectomy, microsurgical decompression, and osteosynthesis. *Neurosurgery*. 1991 Oct;29(4):498-503.
12. Yang KC, Lu XS, Cai QL, Ye LX, Lu WQ. Cervical spondylotic myelopathy treated by anterior multilevel decompression and fusion. Follow-up report of 214 cases. *Clin Orthop Relat Res*. 1987 Aug(221):161-4.
13. Seichi A, Takeshita K, Ohishi I, Kawaguchi H, Akune T, Anamizu Y, et al. Long-term results of double-door laminoplasty for cervical stenotic myelopathy. *Spine(Phila Pa 1976)*. 2001 Mar 1;26(5):479-87.
14. Matsuda Y, Shibata T, Oki S, Kawatani Y, Mashima N, Oishi H. Outcomes of surgical treatment for cervical myelopathy in patients more than 75 years of age. *Spine(Phila Pa 1976)*. 1999 Mar 15;24(6):529-34.
15. Houser OW, Onofrio BM, Miller GM, Folger WN, Smith PL. Cervical spondylotic stenosis and myelopathy: evaluation with computed tomographic myelography. *Mayo Clin Proc*. 1994 Jun;69(6):557-63.

## ORIGINAL ARTICLE

---

### **AUTHORS:**

1. Raju B. Mundhe
2. Arvind B. Goregaonkar
3. Anuraag G. Gupta

### **PARTICULARS OF CONTRIBUTORS:**

1. Assistant Professor, Department of Orthopaedics, Indira Gandhi Government Medical College, Nagpur.
2. Professor & HOD, Department of Orthopaedics, Guide, LTMMC, Sion Mumbai.

### **FINANCIAL OR OTHER**

**COMPETING INTERESTS:** None

3. Special Medical Officer, Department of Orthopaedics, LTMMC, Sion Mumbai.

### **NAME ADDRESS EMAIL ID OF THE CORRESPONDING AUTHOR:**

Dr Raju B. Mundhe,  
Assistant Professor,  
Department of Orthopaedics (M.S. Orthopaedics)  
Indira Gandhi Government Medical College,  
Nagpur.  
E-mail: rajmundhe80@gmail.com

Date of Submission: 12/06/2015.

Date of Peer Review: 13/06/2015.

Date of Acceptance: 01/07/2015.

Date of Publishing: 07/07/2015.